

# Monitoring

## ANIMAL HEALTH

## Increased importance of *Gallibacterium anatis* to poultry

The monitoring data in the Netherlands is showing an increase in the number of cases of illness in layers, in which *Gallibacterium anatis* is involved (see Figure 1). The same situation is being seen internationally. *G. anatis* can occur without clinical symptoms, but can also lead to serious respiratory and fertilisation problems, problems in egg production, and even mortality. It initially resembles *E. coli*. It is not known why the bacteria sometimes cause clinical symptoms and sometimes not. Mitigating factors may be important (stress, co-infections, et cetera), as in the case of *E. coli*.

When there is simultaneous infection with *G. anatis* and other pathogens, such as *Avibacterium paragallinarum* (Coryza) or the IB virus, the pathogens may reinforce one another, resulting in more serious illness. If *G. anatis* is involved, we often also see *E. coli*. As *E. coli* multiplies more easily following the death of the host (the chicken), *E. coli* bacteria can quickly overrun the *G. anatis* bacteria, so that the role played by *G. anatis* in the disease process is easily missed. No distinction can be made in the macroscopic images of the two diseases during necropsy. GD is currently researching the incidence of carrier status of *G. anatis*.

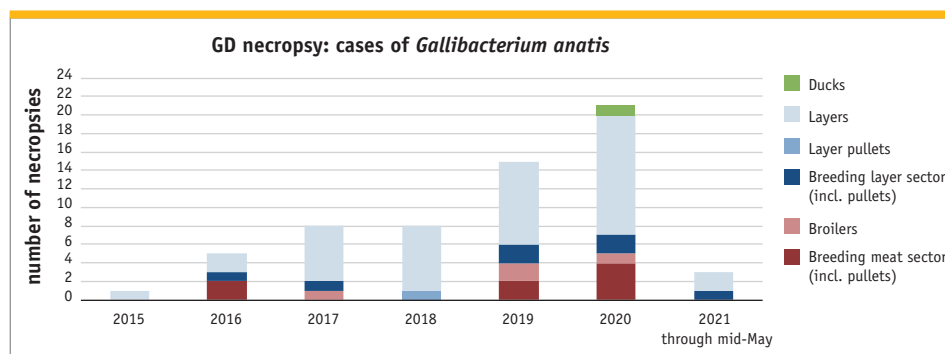


Figure 1. GD necropsy: cases whereby *G. anatis* was involved in the period 2015 through mid-May 2021

## Marek's disease in regular broilers

Marek's disease is sometimes diagnosed in broilers, but this mainly concerns slower growing broilers. An important factor which plays a role is that the virus is shed lifelong following infection, so that the older the broilers, the longer they will continue to shed the virus, thus resulting in an ever-increasing viral risk in their living environment. Due to their relatively short life cycle, regular broilers therefore seldom show clinical Marek problems in the Dutch poultry sector. However, the animal disease monitoring recently diagnosed clinical problems at two farms housing regular broilers. The illness in these animals became apparent due to neural issues and notably 'floppy necks' (see Photo 1). Pathological examination often showed only very slight swelling of the spleen. Besides the formation of tumours and damage to the nervous system, Marek's virus can affect immunity. As a result of this, a range of (milder) disease issues will be noticed in the affected flocks, prior to the actual neural problems. >>

GD has a number of special tests for the Marek virus, which distinguish between vaccine strains and field strains (see yellow box).

### Three forms of Marek

Marek's disease is an important, highly contagious neoplastic disease in chickens. Although chickens can become infected at any age, it is mainly the infections at a young age which result in the formation of tumours and in mortality. Three main forms of this disease may be distinguished: the classical (neural), acute (visceral) and ocular forms.

#### Classical Marek

This form of Marek causes paralysis symptoms whereby the sciatic nerve (nervus ischiadicus) is often damaged (on one side). Although this nerve is seldom seen to be thickened on pathological examination of the chickens, microscopic examination does show damage. Central neurological symptoms may also occur in broilers due to damage to the brain, resulting in the typical 'floppy necks' very suggestive of botulism. The main difference however is that the muscles are not weakened.

#### Acute Marek

The acute (visceral) form is characterised by sudden increased losses due to tumours forming in internal organs (mainly the ovaries, liver, heart, kidneys, spleen, lungs, breast/skeleton/stomach muscles), usually without prior symptoms. The animals may also appear lethargic and emaciated. Recently, slower growing broilers have been seen to have tumours forming in the proventriculus, alongside the central neural issues already mentioned.

#### Ocular Marek

In the ocular form, which mainly affects older animals, the pupils are smaller than normal and are irregular, and the iris is pale.

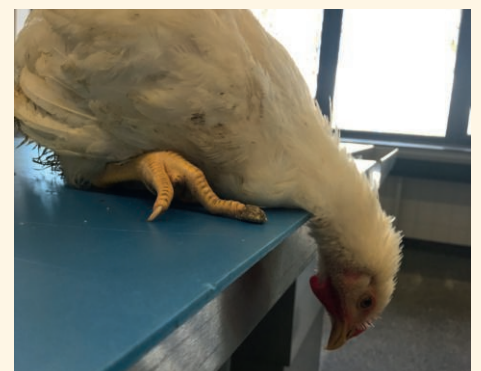### Diagnosing Marek's disease

Although all three forms are easily recognisable in older animals upon pathological examination, the diagnosis is sometimes missed upon quick necropsy of broilers on location due to the often minimal or even absent macroscopic anomalies. Diagnosis can be made by a combination of a PCR test and histopathological (microscopic) tissue examination. In the case of tumour formation, the use of classical histological examination is sometimes ineffective in distinguishing this disease versus avian leucosis. In such cases, additional staining techniques may provide the solution for microscopic tissue examination. GD has a number of PCR tests for Marek's disease, which can demonstrate the presence of the field virus and/or vaccine virus (Rispens, SB1, HVT) in dust samples, FTA cards, feather points, swabs and organs.

However, detection of the field virus in one of these types of samples does not automatically mean that the animals have Marek's disease. For proper diagnosis, there must be proof that the tumours found are associated with the virus of Marek's disease, or that they have the typical microscopic characteristics of this disease, in the brain or nervous system, for example.

### PCR tests for Marek at GD

GD has a number of special tests for the Marek virus, which distinguish between vaccine strains and field strains. They are also referred to as DIVA (Differentiating Infected from Vaccinated Animals) tests. If you wish to have samples tested for presence of the field virus, the 'Marek Rispens DIVA-PCR' is generally the best test. Chickens vaccinated with HVT, for example in some *in ovo* vaccinations, will test negative. The commonly used Rispens vaccine is detected and reported separately in the results, as well as testing for Marek viruses other than Rispens and HVT. One and the same test can therefore detect both Rispens (from the vaccination) and the field virus in a chicken. This is an important feature of the test, as the field virus and vaccine virus can coexist in the same chicken and be constantly shed throughout its life. Do you have any specific questions, on chickens vaccinated with SB1 for example, or on the detection of the HVT vaccine? GD also has separate (DIVA) PCR tests for that purpose.



**Photo 1.** A broiler with a 'floppy neck' infected with the Marek virus. The animal cannot hold its head up, and the symptoms can resemble botulism.

# A number of cases of *Eimeria necatrix* and *Eimeria brunetti* in broilers

Coccidiosis is a collective name for seven disorders caused by the *Eimeria* parasite. Early this year, coccidiosis caused by *Eimeria necatrix* and *Eimeria brunetti* was diagnosed in slower growing broilers. Necropsy showed *E. necatrix* in a flock of organically farmed broilers of four weeks old where there were increased losses, approximately 1 percent within two days at the time of reporting. *E. brunetti* was detected in a flock of broilers of a slower growing concept, of six weeks old, submitted due to respiratory issues. Pathological results showed the flock to be infected with *E. brunetti*, and the diagnosis was confirmed by means of PCR testing. No other pathogens were found. In the week following the discovery, feed intake dropped by 5 percent.

Both *E. necatrix* and *E. brunetti* cause intestinal inflammation. In severe cases, intestinal haemorrhaging occurs and the broilers may die of the infection. These types of coccidiosis are generally seen in chickens older than six weeks and are therefore mainly found in pullets. Over the past years, both *E. necatrix* and *E. brunetti* have been found once before in broilers.

## Diagnosing *Eimeria necatrix*

The diagnosis of *E. necatrix* is relatively simple upon necropsy. The parasite can be found in the second half of the small intestine. In minor infections, white and red spots are visible on the outside of the intestines and the intestinal contents may locally contain mucus. In serious infections, a large section of the intestines is thickened and swollen, with a thick layer of mucus on the intestinal wall, along with visible haemorrhaging. Caecal cores may be present.

## Diagnosing *Eimeria brunetti*

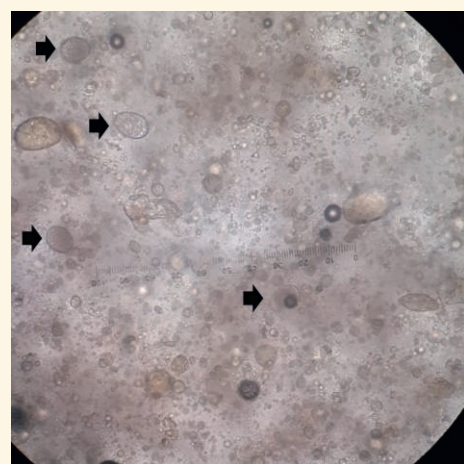
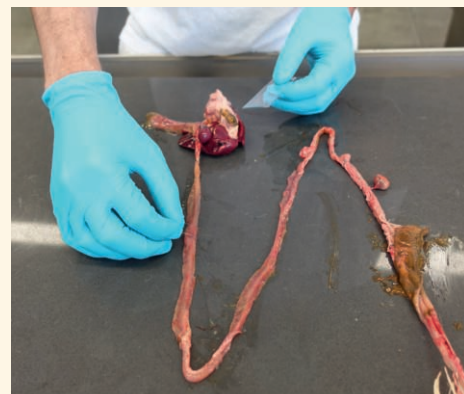
*E. brunetti* is often more difficult to diagnose. The parasite infects the terminal small intestine, the caecum and the large intestine. In mild cases, there will be a local intestinal disorder, and the contents may be somewhat grey or contain salmon-coloured

flakes. In more serious infections, the intestinal wall is thickened, with haemorrhaging and fibrin strands in the intestine. This may be particularly visible in the caecum. One possibility to confirm the infection is to take a scraping of the intestine (intestinal wall and contents) for microscopic examination, or to submit it for the coccidiosis qPCR.

## Treatment

Coccidiosis can be treated using toltrazuril, sulphonamides or amprolium. When using the first two treatments however, a long waiting time must be observed. Prevention of the disease requires the use of anti-coccidiosis treatments or vaccination. Vaccines are available to treat the full spectrum of chicken eimeria parasites, as well as vaccines designed for a limited number of species. This only provides immunity for the species contained in the vaccine. In both *E. brunetti* cases and one of the *E. necatrix* cases, a vaccine had been used which did not contain these species. In such cases, biosecurity may help prevent infection. The infection may also be suppressed by means of cleaning and disinfection, aimed at coccidiosis, in order to prevent manifestation of the clinical disease. In the recent *E. necatrix* case, a full spectrum vaccine had been used, there was probably a high risk of infection due to the age at which the problems arose. Cleaning and disinfection aimed at *Eimeria* can prevent a high risk of infection. However, the parasite can survive in the ground for a number of months, and a free ranging area is difficult to keep clean.

The aforementioned cases are the first cases of *E. necatrix* and *E. brunetti* described in slower-growing or organically farmed broilers. It seems unlikely that these species of eimeria are commonly prevalent. It is however important to keep these species in mind in the event of (vague) problems and to undertake extra diagnostics where necessary.



**Photos: sampling and imaging of oocysts (arrows) and faecal particles seen through a microscope. The diagnosis of coccidiosis can be confirmed by taking a scraping of the intestinal wall for microscopic examination. Based on the size of the oocysts, the location of the sample and the intestinal anomalies, it is possible to diagnose the species of eimeria. A scraping can be submitted for the Coccidiosis (*Eimeria*) qPCR test to confirm less commonly occurring species of eimeria.**

# Animal health barometer for poultry 1<sup>st</sup> quarter 2021

Veterinary diseases	Brief description (numbers at farm level)	1 <sup>st</sup> quarter 2021	2 <sup>nd</sup> quarter 2021	3 <sup>rd</sup> quarter 2021	4 <sup>th</sup> quarter 2021	TREND (OVER 2 YEARS)
<b>Article 15 GWWD (Health &amp; Welfare Act) diseases (diseases named in articles 3 and 7 of the 'Rules for prevention, control and monitoring of infectious animal diseases and zoonoses and TSEs')</b>						
Avian influenza in the Netherlands (H5/H7) <small>(Source: GD, WBVR, national government)</small>	<b>HPAI (H5/H7):</b>	H5N8: 2 farms				↑
	<b>LPAI (H5/H7):</b>	Not detected				-
	<b>Serology (first detection in flock):</b> (Antibodies for H5/H7)	H5N2: 1 farm				-
ND in the Netherlands <small>(Source: GD, OIE)</small>	Commercial poultry	Not detected				-
<b>Salmonellosis (non-zoonotic salmonella)</b> <small>(Source: GD)</small>						
	<i>Salmonella arizonae</i>	N/A				N/A
	<i>Salmonella Gallinarum</i> (SG)	Not detected				-
	<i>Salmonella Pullorum</i> (SP)	Not detected				-
<i>M. gallisepticum</i> <sup>A</sup> <small>(Source: GD)</small>	<b>Serological monitoring by GD:</b>					
	Reproduction sector:	0 farms				-
	Layer pullets:	0 farms				-
	Layers:					
	- not vaccinated and infected:	0 farms				-
	- vaccinated and infected:	1 farm				↓
	Turkeys:	0 farms				-
	<b>Reports in EWS<sup>C</sup> based on positive serology and/or voluntary PCR testing:</b>					
	Layers:	2 farms				↓
	Backyard poultry	-				-
<b>Article 100 GWWD (Health &amp; Welfare Act) diseases (diseases named in article 10 of the 'Rules for prevention, control and monitoring of infectious animal diseases, zoonoses and TSEs')</b>						
Campylobacteriosis	No data available	-	-	-		N/A
<b>Salmonellosis (zoonotic salmonella) (at the flock level)</b> <small>(Source: NVWA)</small>						
S. Enteritidis	Reproduction:	1 flock				-
	Layer pullets:	0 flocks				-
	Layers:	5 flocks				↓
S. Typhimurium	Reproduction:	3 flocks				-
	Layer pullets:	0 flocks				-
	Layers:	0 flocks				-
Other types of salmonella (S. Hadar, S. Infantis, S. Java, S. Virchow)	Reproduction:	0 flocks				↑

>>

- ↑ Increase or strong increase
- ↑ Limited increase
- Situation unchanged
- ↓ Limited decrease
- ↓ Decrease or strong decrease

<sup>A</sup> Based on serological monitoring

<sup>B</sup> Based on serological monitoring and/or the differentiating M.s.-PCR

<sup>C</sup> Early Warning System

Table continuation

Veterinary diseases	Brief description (numbers at farm level)	1 <sup>st</sup> quarter 2021	2 <sup>nd</sup> quarter 2021	3 <sup>rd</sup> quarter 2021	4 <sup>th</sup> quarter 2021	TREND (OVER 2 YEARS)
<b>Other OIE-list poultry diseases in the Netherlands subject to compulsory notification</b>						
Avian chlamydia (Source: GD)		Not detected by GD				-
Infectious laryngotracheitis (ILT) (Source: GD; EWS)	<b>Reported in EWS<sup>c</sup>:</b> Broilers: Backyard poultry:	1 farm 1 case				- -
<i>M. synoviae</i> <sup>b</sup> (Source: GD)	<b>Serological monitoring and/or dPCR GD:</b>			<b>% of positive farms versus farms tested</b>		
	Grandparent stock (incl. pullets) (meat):	0%				-
	Broiler breeder pullets:	4%				-
	Broiler breeders:	11%				↑
	Reproduction sector - laying (incl. rearing, except rearing layers):	0%				-
	Layer breeders:	3%				-
	Layer pullets:	27%				-
	Layers:	73%				-
	Turkeys:	19%				↑
Infectious bronchitis (IB) (Source: GD)	<b>Types most commonly detected by GD:</b> Broilers: Layers:		D388 4-91/D181			
Gumboro (IBD) (Source: GD; EWS)	<b>Reported in EWS<sup>c</sup>:</b> Broilers:	5 farms				↓
Turkey Rhinotracheitis (TRT) (Source: GD)	<b>Detected by GD:</b> Broilers: Layers	2 farms 1 farm				
<b>Other poultry diseases</b>						
Erysipelas ( <i>Erysipelothrix rhusiopathiae</i> ) (Source: GD)	<b>Detected by GD: (new infections):</b> Layer breeders: Layers:	1 farm 4 farms				- -
Histomonosis (Source: GD)	<b>Detected by GD:</b> Reproduction (meat sector): Layer pullets:	6 farms 2 farms				↑ -
<i>Avibacterium paragallinarum</i> (Source: GD; EWS)	<b>Reported in EWS<sup>c</sup>:</b> Layers: Backyard poultry:	3 farms 2 cases				↓ ↑
<i>Pasteurella multocida</i> (Source: GD)	<b>Detected upon necropsy:</b> Layer pullets Layers:	1 farm 4 farms				- -
<b>No reports to the NVWA</b>						

## Animal health monitoring

Since 2002, Royal GD has been responsible for animal health monitoring in the Netherlands, in close collaboration with the veterinary sectors, the business community, the Ministry of Agriculture, Nature and Food Quality, vets and farmers. The information used for the surveillance programme is gathered in various ways, whereby the initiative comes in part from vets and farmers, and partly from Royal GD. This information is fully interpreted to achieve the objectives of the surveillance programme – rapid identification of health issues on the one hand and monitoring trends and developments on the other. Together, we team up for animal health, in the interests of animals, their owners and society at large.